

Safety of Ultrasound Contrast Agents in Patients With Known or Suspected Cardiac Shunts

Jeremy M. Parker, MD^a, Mark W. Weller, JD^b, Linda Maiman Feinstein, JD^b, Robin J. Adams, BS^b, Michael L. Main, MD^c, Paul A. Grayburn, MD^d, David O. Cosgrove, MD^e, Barry A. Goldberg, MD^f, Kassa Darge, MD, PhD^g, Petros Nihoyannopoulos, MD^h, Stephanie Wilson, MDⁱ, Mark Monaghan, PhD^j, Fabio Piscaglia, MD^k, Brian Fowlkes, PhD^l, Wilson Mathias, MD^m, Fuminari Moriyasu, MD, PhDⁿ, Maria Christina Chammas, MD, PhD^m, Lennard Greenbaum, MD^o, and Steven B. Feinstein, MD^{a,*}

Contrast-enhanced ultrasound imaging is a radiation-free diagnostic tool that uses biocompatible ultrasound contrast agents (UCAs) to improve image clarity. UCAs, which do not contain dye, often salvage “technically difficult” ultrasound scans, increasing the accuracy and reliability of a front-line ultrasound diagnosis, reducing unnecessary downstream testing, lowering overall health care costs, changing therapy, and improving patient care. Two UCAs currently are approved and regulated by the US Food and Drug Administration. They have favorable safety profiles and risk/benefit ratios in adult and pediatric populations, including compromised patients with severe cardiovascular diseases. Nevertheless, these UCAs are contraindicated in patients with known or suspected right-to-left, bidirectional, or transient right-to-left cardiac shunts. These patients, who constitute 10% to 35% of the general population, typically receive no UCAs when they undergo echocardiography. If their echocardiographic images are suboptimal, they may receive inappropriate diagnosis and treatment, or they may be referred for additional diagnostic testing, including radiation-based procedures that increase their lifetime risk for cancer or procedures that use contrast agents containing dye, which may increase the risk for kidney damage. An exhaustive review of current peer-reviewed research demonstrated no scientific basis for the UCA contraindication in patients with known or suspected cardiac shunts. Initial safety concerns were based on limited rodent data and speculation related to macroaggregated albumin microspheres, a radioactive nuclear imaging agent with different physical and chemical properties and no relation to UCAs. Radioactive macroaggregated albumin is not contraindicated in adult or pediatric patients with cardiac shunts and is routinely used in these populations. In conclusion, the International Contrast Ultrasound Society Board recommends removal of the contraindication to further the public interest in safe, reliable, radiation-free diagnostic imaging options for patients with known or suspected cardiac shunts and to reduce their need for unnecessary downstream testing. © 2013 Elsevier Inc. All rights reserved. (Am J Cardiol 2013;112:1039–1045)

Ultrasound contrast agents (UCAs) are radiation-free substances that improve ultrasound image clarity. UCAs often are used to salvage “technically difficult” ultrasound scans, for example, when ultrasound signal transmission is impaired by obesity or other physical impediments.

Contrast-enhanced ultrasound imaging and UCAs produce images in real-time using equipment that is portable and widely available. By increasing the reliability of front-line ultrasound scans, UCAs provide a more accurate initial diagnosis, reduce the need for downstream testing, lower overall health care costs, change therapies, and improve patient care without exposing patients to ionizing radiation or increasing the risk for nephrotoxicity.¹ In the United States, 2 commercial UCAs, Optison (GE Healthcare, Milwaukee, Wisconsin) and Definity (Lantheus Medical Imaging, North Billerica, Massachusetts), are approved and regulated by the US Food and Drug Administration (FDA). The 2 UCAs currently are contraindicated in patients with known or suspected cardiac shunts, who constitute 10% to 35% of the general population.^{2–5} Physicians representing the International Contrast Ultrasound Society raised concerns about the current contraindication and its impact on patient care during a September 11, 2012, professional society briefing on the safety of UCAs to staff members of the Center for Drug Evaluation and Research at the FDA.

^aRush University Medical Center, Chicago, Illinois; ^bDentons US LLP, Washington, District of Columbia; ^cSt. Luke’s Mid America Heart Institute, Kansas City, Kansas; ^dBaylor University Medical Center, Dallas, Texas; ^eImperial College London, London, United Kingdom; ^fThomas Jefferson University, Philadelphia, Pennsylvania; ^gChildren’s Hospital of Philadelphia, Philadelphia, Pennsylvania; ^hHammersmith Hospital, London, United Kingdom; ⁱUniversity of Calgary, Calgary, Alberta, Canada; ^jKing’s College Hospital, London, United Kingdom; ^kUniversity of Bologna, Bologna, Italy; ^lUniversity of Michigan, Ann Arbor, Michigan; ^mUniversity of Sao Paulo, São Paulo, Brazil; ⁿTokyo Medical University, Tokyo, Japan; and ^oWinnie Palmer Hospital, Orlando, Florida. Manuscript received January 30, 2013; revised manuscript received and accepted May 8, 2013.

See page 1044 for disclosure information.

*Corresponding author: Tel: (312) 942-4601; fax: (312) 942-6224.

E-mail address: sfeinste@rush.edu (S.B. Feinstein).

Table 1
Commercial ultrasound contrast agents

Manufacturer	Name	Type	Development Stage
Accusphere	Imagify	Polymer/perfluorocarbon	Clinical development
Alliance/Schering	Imavist	Encapsulated perfluorocarbon	Clinical development
Bracco	SonoVue	Lipid/sulfur hexafluoride	Approved outside the United States
Bracco	SonoRx	Simethicone-coated cellulose	Approved outside the United States
Byk-Gulden	BY963	Lipid/air	Clinical development
Lantheus Medical Imaging	Definity	Perflutren lipid microspheres	Approved for use
GE Healthcare	Optison	Perflutren protein type A microspheres	Approved for use
GE Healthcare/Daiichi	Sonazoid	Lipid/perfluorocarbon microspheres	Approved outside the United States
MBI/Mallinckrodt	Albunex	Sonicated albumin microspheres	Approved for use
Schering	Echovist	Reconstituted galactose granules	Approved outside the United States
Schering	Levovist	Galactose and palmitic acid granules	Approved outside the United States
Schering	Sonovist	Polymer/air	Clinical development

International Contrast Ultrasound Society representatives committed to prepare a technical report to assess current peer-reviewed research. Key findings of this study include the following: (1) Current published research is replete with peer-reviewed studies demonstrating the safety and clinical benefits of commercial UCAs in adult and pediatric populations, including patients with severe cardiovascular diseases, (2) the contraindication is not evidence based, (3) initial safety concerns were based on limited rodent data that have not corresponded with human data along with speculation pertaining to a radioactively-tagged nuclear imaging contrast agent with physical and chemical properties unlike those of UCAs, (4) the nuclear imaging agent is not contraindicated in patients with known or suspected cardiac shunts, and (5) the cumulative weight of scientific evidence supports the use of UCAs in adult and pediatric patients with known or suspected cardiac shunts.

Noncommercial and Commercial Ultrasound Contrast Agents

All UCAs are suspensions of biocompatible gas-filled microbubbles or microspheres that reflect ultrasound signals. They are administered during a diagnostic ultrasound examination either intravenously or by direct catheter infusions (to the bladder, uterus, Fallopian tubes, etc.). UCAs may be used for parenteral injections (blood pool agents) or enteral injections (gastrointestinal or intraorgan injection, bladder or Fallopian tube infusions). UCAs traverse the microvasculature at physiologic transit times, generating contrast effects that highlight anatomic boundaries (vascular vs nonvascular tissues and organs) and define microvascular tissue perfusion. Contrast effects are produced by the interface between the gas and the surrounding shell, which creates an acoustic mismatch that increases the signal-to-noise ratio between the blood and tissue.

Presently, there are 2 types of UCAs: noncommercial hand-agitated UCAs (not regulated by the FDA), which are produced at the bedside by manually agitating a solution, such as saline, to create a suspension of ultrasound-reflective gas-filled microbubbles, and commercial UCAs (Optison and Definity), which are produced under controlled conditions regulated by the FDA. The commercial agents contain suspensions of microspheres composed of an outer shell

(either albumin or a phospholipid) encapsulating a perfluorocarbon gas. Optison is composed of perflutren protein type A microspheres for injectable suspension. Definity is a perflutren lipid microsphere injectable suspension,

The first UCAs were hand-agitated suspensions of microbubbles created by trial and error. Claude Joyner is credited with describing the initial hand-agitated microbubbles, and Gramiak and Shah, in 1968, published the first report describing the use of these microbubbles as a UCA.^{6,7} Feigenbaum et al⁸ subsequently expanded this work and used manually agitated indocyanine green as a UCA.

Today, noncommercial UCAs are widely used in clinical practice, and their method of production has not changed since 1968. Typically, 2 syringes connected by a stopcock are used to rapidly mix a solution of bacteriostatic saline (9 cm³) and room air (1 cm³), producing a transient suspension of microbubbles measuring 31.6 ± 8.2 μm.^{9,10} Because the mean size of these manually agitated microbubbles may be 5 to 10 times larger than the mean size of the microspheres constituting commercial UCAs, they expose patients to larger volumes of gas and are limited in their ability to pass through lung capillaries, reducing visualization of the left-sided heart chambers. In addition, manually agitated microbubbles are variable in size and concentration, and because they do not contain stabilizing shells, they must be used within seconds to minutes.

The first generation of commercial, FDA-approved UCAs consisted of nitrogen-based gases encapsulated with protein shells (Albunex; Molecular Biosystems, Inc., San Diego, California) or finely milled particulate matter that was hydrophilic (Levovist; Bayer AG, Leverkusen, Germany).^{11,12} Coincident with the development of commercial UCAs, ultrasound equipment manufacturers developed newer, more sophisticated harmonic imaging software that produced significant enhancement of the signal-to-noise ratio while using a lower mechanical index.¹³

Second-generation commercial UCAs (Optison and Definity) use perflutren gas, a low-soluble gas with high molecular weight, to extend in vivo persistence. The perflutren microspheres are smaller and more stable than first-generation commercial UCAs and are capable of crossing the pulmonary capillary bed. This permits more efficient noninvasive imaging of the left-sided cardiac chambers and assessment of myocardial perfusion.^{14–16}

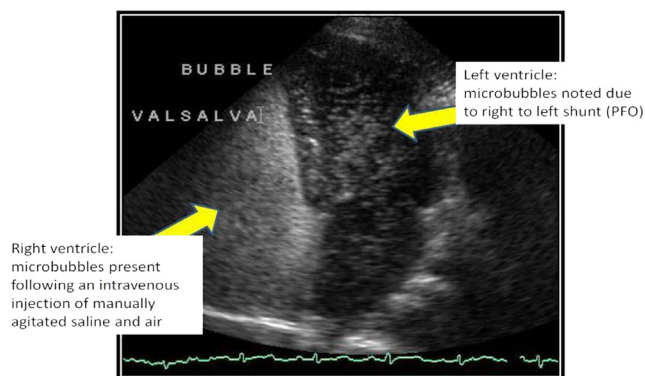


Figure 1. Echocardiographic still image: intravenous injection of manually agitated saline in a patient with a marked right-to-left cardiac shunt. Note the blush of agitated saline in the left ventricular chamber. Study performed October 30, 2012. Image provided by Michael Main, MD (St. Luke's Mid America Heart Institute, Kansas City, Missouri).

Third-generation “designer” UCAs are in development for molecular imaging. They are uniquely and specifically labeled to permit quantitative, physiologic localization (“molecular imaging”) of inflammation and related disease states.

In addition, fourth-generation therapeutic UCAs are in development and have achieved success in preclinical studies. Therapeutic UCAs will carry genes and drugs to tumors and specific organ systems throughout the body, serving as ultrasound-directed, site-specific drug or gene therapeutic delivery platforms.^{17,18} A summary of developmental or approved commercial UCAs is listed in Table 1.

Clinical Ultrasound Contrast Agent Use

Agitated saline solutions are widely used in adult and pediatric populations without regulatory oversight or contraindication. Echocardiography laboratories throughout the United States use agitated saline solutions during transthoracic echocardiography and transesophageal echocardiography to detect cardiac shunts, including patent foramen ovale, a condition occurring in approximately 10% to 35% of the general population.^{2–5} Radiology and neurology ultrasound laboratories also use noncommercial UCAs during transcranial Doppler imaging for the detection of cardiac shunts (Figure 1).¹⁹ In addition, agitated saline solutions are used to evaluate atrial septal defects, sinus venosus defects, persistent left superior vena cava, intrapulmonary shunting, and exercise-induced transpulmonary shunting. Pediatric congenital cardiac defects also are routinely identified with noncommercial hand-agitated saline UCAs.²⁰

Commercial UCAs typically are used in the United States to enhance suboptimal echocardiographic studies for the delineation of left ventricular endocardial borders and opacification.²¹ An estimated 10% to 30% of all transthoracic echocardiographic studies are considered suboptimal.^{1,22,23} UCA enhancement of suboptimal echocardiographic exams is addressed by contrast-enhanced ultrasound echocardiographic guidelines adopted by the American Society of

Echocardiography (in 2000 and 2008) and the European Society of Echocardiography (in 2009).^{21,24,25}

Commercial UCAs also are used off label during stress echocardiography and transesophageal echocardiography and for imaging the liver, prostate, brain, and other noncardiac structures.¹⁸ UCAs must be used off label for the enhancement of suboptimal stress echocardiographic studies unless alternative imaging plans are in place, on the basis of accreditation standards for adult echocardiography laboratories adopted in 2010 by the Intersocietal Accreditation Commission (known at the time as the Intersocietal Commission for the Accreditation of Echocardiography Laboratories). In addition to these intravenously administered UCA applications, nonintravenous off-label indications include use in hysterosalpingo-sonographic detection of Fallopian tube patency as well as voiding urosonography for the diagnosis of vesicoureteric reflux in pediatric patients.^{26,27} Outside the United States, where UCAs have a broader range of regulatory approvals, commercial UCAs also are used for the detection and assessment of myocardial perfusion, tumors, gastrointestinal disorders, and numerous other indications.

Ultrasound Contrast Agent Safety

The safety of Optison and Definity, the 2 FDA-approved UCAs, is well established. FDA advisory panels evaluated their safety most recently on June 24, 2008, and May 2, 2011, and the agency has 3 times downgraded UCA package insert contraindications and warnings. In addition, the peer-reviewed research is now replete with studies demonstrating the safety of commercial UCAs in pediatric and adult populations, including patients with congestive heart failure, pulmonary hypertension, and other severe cardiovascular diseases. Data also demonstrate the safety of UCAs in the pediatric population, with a low risk-to-benefit ratio and improved care in these young patients.²⁸

As noted, hand-agitated UCAs are produced at the bedside without the benefit of regulatory oversight. They contain microbubbles that are larger, more variable in size and less stable than commercially produced UCA microspheres. Nevertheless, hand-agitated UCAs have a low record of complications and generally are administered without hemodynamic or neurologic risk. Only isolated cases of transient adverse neurologic events have been reported, despite the continued high volume of hand-agitated microbubble procedures.

Safety data for hand-agitated UCAs include animal studies and clinical case reports. Animal data suggest that after mixing 9 cm³ of agitated saline with 1 cm³ of air, a large bolus of gas (20 ml/min) or a continuous bolus of gas (11 ml/min) injected intravenously would be required to generate intra-arterial bubbles.²⁹ Other animal data demonstrate that injections of 2 ml of air in the radial artery are sufficient for passage into the cerebral system.³⁰ In addition, case reports and case series have described neurologic events associated with the administration of an agitated air-saline mixture in patients with cardiac shunts.^{31–34} A further study of transcranial Doppler and echocardiographic evaluations demonstrated stroke symptoms in a series of 5 patients after the administration of manually agitated

Table 2
Comparison of macroaggregated albumin and ultrasound contrast agents

Agent	Particle Sizes	Potential Occlusion Level	FDA Label
MAA	10–150 μm (90% from 10 to 70 μm), maximum 150 μm	Arterioles (size 20–30 μm)	Precaution
Optison	Mean 3–4.5 μm (95% <10 μm), maximum 32 μm	Capillaries (size 5–10 μm)	Contraindication and box warning
Definity	Mean 1.1–3.3 μm (98% <10 μm), maximum 20 μm	Capillaries (size 5–10 μm)	Contraindication and box warning

microbubble solutions; these cases represented a small sample of >3,000 manually agitated saline studies performed at the reporting institutions.³⁵ A report of the American Society of Echocardiography assessed the risk for side effects from contrast (including saline and indocyanine green) at 0.062% and concluded that the low risk for adverse events is outweighed by the significant diagnostic benefits of contrast imaging.³⁶

Radioactively Tagged Macroaggregated Albumin

Nuclear medicine procedures routinely utilize radioactively tagged macroaggregated albumin (MAA) as a diagnostic agent for detection of pulmonary emboli. MAA also has been used to detect and quantify the presence and degree of cardiac shunting in adult and pediatric populations.^{37–41} MAA contains solid albumin particles that are significantly larger in size than UCA microspheres or microbubbles and have a longer half-life. In fact, technetium-labeled MAA (Pulmolite; Pharmed, Bedford, Massachusetts) has an average particle size of 15 to 30 μm , which is 5 to 10 times the average size of Definity and Optison microspheres. Moreover, 90% of Pulmolite MAA particles are 10 to 70 μm in diameter, and some may be as large as 150 μm . Despite the relatively large size and radioactive composition of these Pulmolite MAA particles, as well as the theoretic potential for direct passage into the arterial system without filtration by the lung capillary bed, current Pulmolite prescribing information contains a “precaution” for use in detecting a cardiac shunt.

Genesis of Ultrasound Contrast Agent Contraindication for Shunts

In 1994, when the FDA approved the first commercial UCA (Albunex), exhaustive published research demonstrated the safety of UCAs in adult and pediatric patients with right-to-left shunts, pulmonary disease, and pulmonary hypertension. Albunex initially was classified as a device, and prescribing information did not contain a warning or contraindication for intra-arterial infusions or for use in patients with cardiac shunts. Moreover, there was no evidence associating Albunex with measurable hemodynamic effects when injected directly into the left main coronary artery in patients with known or suspected stable coronary artery disease.⁴² Similarly, direct aortic root injections provided a safe profile.⁴³ Indeed, Albunex was used safely in >25,000 injections (17,000 patient exams) from 1994 to 1997, with no reported events involving transient ischemic attacks or cerebral vascular accidents associated with its administration.

In 1997, Albunex was replaced by Optison, the second commercial UCA to be approved by the FDA. The original

Optison prescribing information included a warning that extreme caution should be used when administering Optison in patients with right-to-left, bidirectional, or transient right-to-left shunts, because such patients had not been directly studied.

The concern regarding the use of Optison in patients with known or suspected cardiac shunts appears to have been expressed for the first time during a meeting of an FDA advisory panel on February 24, 1997, before the approval of Optison. A transcript of that meeting includes discussion speculating that the physical and chemical properties of the commercial UCA under discussion may be similar to those of radioactively tagged MAA. This speculation was not subjected to scientific scrutiny at that time and is not supported by research today. As 1 panelist, Dr. Alazraki, stated, “The panel was acting in absence of data.”⁴⁴

The advisory panel also noted that 95% of Optison microspheres were <5 μm in diameter (Table 2), and any larger microspheres generally would be filtered by the lungs after intravenous injection. It was theorized that a cardiac shunt could potentially cause those larger microspheres to bypass the filtering mechanism of the lungs, leading to possible arteriolar and capillary obstruction. Nonetheless, a majority of the advisory panel concluded that no further postmarketing data were necessary given the already widespread use of unregulated manually agitated saline microbubbles in patients with known or suspected cardiac shunts. As Dr. Vogel, a consultant to the sponsor (Molecular Biosystems, Inc.) and chief of cardiology at Yale stated, “Without FDA regulation, there has been a considerable experience in the clinical world with the use of agitated saline and agitated contrast. This is a totally unregulated practice. But what we know of it there is that there is a tremendous heterogeneity of the size of bubbles. There is a confluence and a growth of bubbles in fairly unregulated fashion. These technologies or clinical technologies have been used for a number of years to detect shunts and have been used in patients with all different kinds of neurological, cardiac, and pulmonary impairments. To my knowledge, done appropriately, there have been no untoward effects observed with significantly more administration of gas than would be present in the proposed study. So I would think that—and I agree with the panel’s concern on a new type of device. We want to make sure it is safe. But I must confess that I see no reason really to be concerned about neurological events in shunt patients because we have been giving agitated saline and agitated contrast with far more content of gas to specifically these kinds of patients for many years.”⁴⁴ Optison was thus approved with no contraindication for known or suspected cardiac shunts.⁴⁴

The third commercial UCA (Definity) received regulatory approval in 2001, subject to the first FDA-mandated

Table 3
Peer-reviewed publications: safety of commercial ultrasound contrast agents

Study	n	Clinical End Points	Significant Findings
Kusnetzky et al ⁴⁸	6,196	Short-term mortality	No increase in mortality in hospitalized patients
Main et al ⁴⁹	58,254	Short-term mortality	No increase in mortality in hospitalized patients with UCA; lower risk-adjusted mortality
Herzog ⁵⁰	16,025	SAE rate	Serious nonfatal reactions in 0.03%
Wei et al ⁵¹	78,383*	SAE rate	Serious nonfatal reactions in 0.01%
Dolan et al ⁵²	34,447	Short- and intermediate-term events on rest and stress echocardiography	No short-term adverse events with UCA; no increase in MI or mortality
Gabriel et al ⁵³	4,786	SAE on stress echocardiography	No increase in SAE rate
Shaikh et al ⁵⁴	5,069	SAE on stress echocardiography	No increase in SAE rate
Abdelmoneim et al ⁵⁵	10,792	Short- and long-term safety with stress echocardiography	No increase in short- or long-term risk for death or MI
Abdelmoneim et al ⁵⁶	6,164 [†]	Short- and long-term safety in patients with elevated right ventricular systolic pressure	No increase in short- or long-term risk for death or MI
Exuzides et al ⁵⁷	2,900	Short-term mortality in critically ill patients	No increase in mortality in hospitalized patients
Wei et al ⁵⁸	32	Pulmonary hemodynamic study	No hemodynamic changes in controls or patients with mild to moderate pulmonary hypertension
Weiss et al ⁵⁹	1,053	Risk for SAE within 30 minutes of administration	Well tolerated in routine clinical practice; no SAEs

MI = myocardial infarction; SAE = serious adverse event.

* Includes 14,412 patients also reported by Herzog.⁵⁰

[†] These patients were also included in Abdelmoneim et al.⁵⁵

Adapted from Boolani and Main.⁴⁷

Table 4
Food and Drug Administration—mandated postmarketing safety studies for ultrasound contrast agents

Manufacturer	Pulmonary Hemodynamic Study	Critically Ill Propensity-Matched Database	Routine Clinical Care Registry
Lantheus Medical Imaging	No change in PA pressure with Definity; no deaths or SAEs (n = 32)*	15,798 propensity-matched patients; HR 0.683 (95% CI 0.591–0.789)	No deaths or SAEs at 24 hours (n = 1,053) [†]
GE Healthcare	No change in PA pressure with Optison; no deaths or SAEs (n = 30)	2,884 propensity-matched patients [‡] ; HR 1.4 (95% CI 0.965–2.030)	No deaths or SAEs (n = 1,039)

CI = confidence interval; HR = hazard ratio; PA = pulmonary artery, SAE = serious adverse event.

* Data from this study were separately published by Exuzides et al.⁵⁷

[†] Data from this study were separately published by Wei et al.⁵⁸

[‡] Data from this study were separately published by Abdelmoneim et al.⁵⁵

Data are available at <http://www.fda.gov/downloads/AdvisoryCommittees/CommitteesMeetingMaterials/Drugs/CardiovascularandRenalDrugsAdvisoryCommittee/UCM256586.pdf>. Adapted from Boolani and Main.⁴⁷

contraindication for right-to-left, bidirectional, or suspected right-to-left shunts as well as for intra-arterial injection. The contraindications subsequently were applied to Optison as well.

It appears that the contraindication was based on a study performed in rats to examine the passage of Definity microspheres into skeletal muscle capillaries after intra-arterial injection.⁴⁵ The investigators of the study noted that Definity microspheres >5 µm in diameter were entrapped within the small arterioles and capillaries of the rat model after intra-arterial injection. However, they concluded that such entrapment was rare (with a retention fraction of 1.2%) and short lived (with resolution of 85% of retention within 10 minutes) and presented no measurable adverse hemodynamic consequences.⁴⁶ Nonetheless, despite the limited nature of the rat study and the investigators' restricted conclusions, UCAs became contraindicated in patients with known or suspected cardiac shunts as well as for intra-arterial injection.

Since 2001, a compelling body of peer-reviewed scientific data has demonstrated the safety of Definity and Optison in everyday echocardiography practice.⁴⁷ These studies demonstrate safety across a range of patient populations, including hospitalized patients, patients with pulmonary hypertension, and patients who undergo stress echocardiography (Tables 3 and 4).⁴⁷ None of these studies contains evidence demonstrating that these UCAs increase risk for patients with right-to-left, bidirectional, or transient right-to-left cardiac shunts.

Removal of Contraindication

On the basis of peer-reviewed studies demonstrating the safety of current commercial UCAs, it appears that removal of the contraindication for patients with known or suspected cardiac shunts would further the public interest in safe, reliable, radiation-free diagnostic imaging options for 10% to 35% of the general population. In addition, expanding

access to UCAs would reduce the need for unnecessary downstream testing and improve patient care.

SonoVue and Other Investigational Ultrasound Contrast Agents

Bracco's (Milan, Italy) investigational UCA SonoVue is currently under review by the FDA. On the basis of published safety data and physical parameters comparable with those of the currently approved UCAs, there appears to be no scientific or clinical basis for contraindicating SonoVue for patients with known or suspected cardiac shunts. Other companies and other products will need to be assessed on the basis of their individual safety profiles and the physical properties of each agent.

Disclosures

The authors have no conflicts of interest to disclose.

- Kurt M, Shaikh KA, Peterson L, Kurrelmeyer KM, Sha G, Nagueh S, Fromm R, Quinones M, Zoghbi W. Impact of contrast echocardiography on evaluation of ventricular function and clinical management in a large prospective cohort. *J Am Coll Cardiol* 2009;53:802–810.
- Fisher DC, Fisher EA, Budd JH, Rosen SE, Goldman ME. The incidence of patent foramen ovale in 1,000 consecutive patients. A contrast transesophageal echocardiography study. *Chest* 1995;107:1504–1509.
- González-Alujas T, Evangelista A, Santamarina E, Rubiera M, Gomez-Bosch Z, Rodriguez-Palomares J, Avegliano G, Molina C, Alvarez-Sabin J, Garcia-Dorado D. Diagnosis and quantification of patent foramen ovale. Which is the reference technique? Simultaneous study with transcranial Doppler, transthoracic and transesophageal echocardiography. *Rev Esp Cardiol* 2011;64:133–139.
- Movsowitz C, Podolsky LA, Meyerowitz CB, Jacobs LE, Kotler MN. Patent foramen ovale: a nonfunctional embryological remnant or a potential cause of significant pathology? *J Am Soc Echocardiogr* 1992;5:259–270.
- Lynch JJ, Schuchard GH, Gross CM, Wann LS. Prevalence of right-to-left atrial shunting in a healthy population: detection by Valsalva maneuver contrast echocardiography. *Am J Cardiol* 1984;53:1478–1480.
- Gramiak R, Shah PM. Echocardiography of the aortic root. *Invest Radiol* 1968;3:356–366.
- Gramiak R, Shah PM, Kramer DH. Ultrasound cardiography: contrast studies in anatomy and function. *Radiology* 1969;92:939–948.
- Feigenbaum H, Stone JM, Lee DA, Nasser WK, Chang S. Identification of ultrasound echoes from the left ventricle by use of intracardiac injections of indocyanine green. *Circulation* 1970;41:615–621.
- Feinstein SB, Ten Cate FJ, Zwehl W, Ong K, Maurer G, Tei C, Shah PM, Meerbaum S, Corday E. Two-dimensional contrast echocardiography. I. In vitro development and quantitative analysis of echo contrast agents. *J Am Coll Cardiol* 1984;3:14–20.
- Jeon D-S, Luo H, Iwami T, Miyamoto T, Brasch AV, Mirocha J, Naqvi TZ, Siegel RJ. The usefulness of a 10% air-10% blood-80% saline mixture for contrast echocardiography: Doppler measurement of pulmonary artery systolic pressure. *J Am Coll Cardiol* 2002;39:124–129.
- Feinstein SB, Cheirif J, Ten Cate FJ, Silverman PR, Heidenreich PA, Dick C, Desir RM, Armstrong WF, Quinones MA, Shah PM. Safety and efficacy of a new transpulmonary ultrasound contrast agent: initial multicenter clinical results. *J Am Coll Cardiol* 1990;16:316–324.
- Fritzsche T, Hilmann J, Kämpfe M, Müller N, Schöbel C, Siegert J. SHU 508, a transpulmonary echocontrast agent: initial experience. *Invest Radiol* 1990;25(suppl 1):S160–S161.
- Kaul S. New developments in ultrasound systems for contrast echocardiography. *Clin Cardiol* 1997;20:27–30.
- Meza M, Greener Y, Hunt R, Perry B, Revall S, Barbee W, Murgo JP, Cheirif J. Myocardial contrast echocardiography: reliable, safe, and efficacious myocardial perfusion assessment after intravenous injections of a new echocardiographic contrast agent. *Am Heart J* 1996;132:871–881.
- Kitzman DW, Goldman ME, Gillam LD, Cohen JL, Aurigemma GP, Gottdiener JS. Efficacy and safety of the novel ultrasound contrast agent perflutren (Definity) in patients with suboptimal baseline left ventricular echocardiographic images. *Am J Cardiol* 2000;86:669–674.
- Bhatia VK, Senior R. Contrast echocardiography: evidence for clinical use. *J Am Soc Echocardiogr* 2008;21:409–416.
- Feinstein SB. The powerful microbubble: from bench to bedside, from intravascular indicator to therapeutic delivery system, and beyond. *Am J Physiol Heart Circ Physiol* 2004;287:H450–H457.
- Dindyal S, Kyriakides C. Ultrasound microbubble contrast and current clinical applications. *Recent Pat Cardiovasc Drug Discov* 2011;6:27–41.
- Droste DW, Kriete J-U, Stypmann J, Castrucci M, Wichter T, Tietje R, Weltermann B, Young P, Ringelstein EB. Contrast transcranial Doppler ultrasound in the detection of right-to-left shunts comparison of different procedures and different contrast agents. *Stroke* 1999;30:1827–1832.
- Van Hare GF, Silverman NH. Contrast two-dimensional echocardiography in congenital heart disease: techniques, indications and clinical utility. *J Am Coll Cardiol* 1989;13:673–686.
- Mulvagh SL, Rakowski H, Vannan MA, Abdelmoneim SS, Becher H, Bierig SM, Burns PN, Castello R, Coon PD, Hagen ME, Jollis JG, Kimball TR, Kitman DW, Kronzon I, Labovitz AJ, Lang RM, Mathew J, Moir WS, Nagueh SF, Pearlman AS, Perez JE, Porter TR, Rosenbloom J, Strachan GM, Thanigaraj S, Wei K, Woo A, Yu EH, Zoghbi WA. American Society of Echocardiography consensus statement on the clinical applications of ultrasonic contrast agents in echocardiography. *J Am Soc Echocardiogr* 2008;21:1179–1201.
- Broderick TM, Bourdillon PD, Ryan T, Feigenbaum H, Dillon JC, Armstrong WF. Comparison of regional and global left ventricular function by serial echocardiograms after reperfusion in acute myocardial infarction. *J Am Soc Echocardiogr* 1989;2:315–323.
- Senior R, Dwivedi G, Hayat S, Lim TK. Clinical benefits of contrast-enhanced echocardiography during rest and stress examinations. *Eur J Echocardiogr* 2005;6(suppl 2):S6–S13.
- Senior R, Becher H, Monaghan M, Agati L, Zamorano J, Vanoverschelde JL, Mihoyannopoulos P. Contrast echocardiography: evidence-based recommendations by European Association of Echocardiography. *Eur J Echocardiogr* 2009;10:194–212.
- Intersocietal Accreditation Commission. IAC Standards and Guidelines for Adult Echocardiography Accreditation. Available at: <http://www.intersocietal.org/echo/standards/IACAdultEchocardiographyStandards2012.pdf>. Accessed June 7, 2013.
- Holte J, Rasmussen C, Morris H. First clinical experience with sonicated human serum albumin (Albunex®) as an intrafallopian ultrasound contrast medium. *Ultrasound Obstet Gynecol* 1995;6:62–65.
- Renjen P, Bellah R, Hellinger JC, Darge K. Advances in uroradiologic imaging in children. *Radiol Clin North Am* 2012;50:207–218.
- Darge K, Papadopoulou F, Ntoulia A, Bulas DI, Coley BD, Fordham LA, Paltiel HF, McCarville B, Volberg FM, Cosgrove DO, Goldberg BB, Wilson SR, Feinstein SB. Safety of contrast enhanced ultrasound in children for non-cardiac applications. *Pediatr Radiol*. In press.
- Muth CM, Shank ES. Gas embolism. *N Engl J Med* 2000;342:476–482.
- Chang C, Dughi J, Shitabata P, Johnson G, Coel M, McNamara JJ. Air embolism and the radial arterial line. *Crit Care Med* 1988;16:141–143.
- Holcomb BW, Loyd JE, Byrd BF, Wilsdorf TT, Casey-Cato T, Mason WR, Robbins IM. Iatrogenic paradoxical air embolism in pulmonary hypertension. *Chest* 2001;119:1602–1605.
- Kabha M, Barak M. Paradoxical symptomatic air embolism after saline contrast transesophageal echocardiography. *Echocardiography* 2008;25:349–350.
- Srivastava TN, Undesser EK. Transient ischemic attack after air contrast echocardiography in patients with septal aneurysm. *Ann Intern Med* 1995;122:396.
- Dittrich HC. Transient ischemic attack after air-contrast echocardiography. *Ann Intern Med* 1995;123:731–732.
- Romero JR, Frey JL, Schwamm LH, Demaerschalk BM, Chaliki HP, Prikh G, Burke RF, Babikian VL. Cerebral ischemic events associated with “bubble study” for identification of right to left shunts. *Stroke* 2009;40:2343–2348.
- Bommer W, Shah P, Allen H, Meltzer R, Kisslo J. The safety of contrast echocardiography: report of the Committee on Contrast Echocardiography for the American Society of Echocardiography. *Am J Cardiol* 1984;3:6–13.

37. Nagai T, Jimbo M, Sano K. Cerebro-pulmonary scan using macroaggregated albumin as a quantitation of intracerebral arterio-venous shunting. *J Nucl Med* 1967;8:709–722.
38. Gates GF, Orme HW, Dore EK. Cardiac shunt assessment in children with macroaggregated albumin technetium-99m. *Radiology* 1974;112:649–653.
39. Salimi Z, Thomasson J, Vas W, Salimi A. Detection of right-to-left shunt with radionuclide angiocardiology in refractory hypoxemia. *Chest* 1985;88:784–786.
40. Dogan AS, Rezai K, Kirchner PT, Stuhlmuller JE. A scintigraphic sign for detection of right-to-left shunts. *J Nucl Med* 1993;34:1607–1611.
41. Ito K, Kurihara K, Ishibashi A, Morooka M, Mitsumoto T, Minamimoto R, Kubota K. Cut-off value for normal versus abnormal right-to-left shunt percentages using (99m)Tc-macroaggregated albumin. *Nucl Med Commun* 2011;32:936–940.
42. Ten Cate FJ, Widimsky P, Cornel JH, Waldstein DJ, Serruys PW, Waaler A. Intracoronary Alunex. Its effects on left ventricular hemodynamics, function, and coronary sinus flow in humans. *Circulation* 1993;88:2123–2127.
43. Aronson S, Savage R, Fernandez A, Klein A, Young C, Toledano A, Lee BK, Karp RB, Lytle B, Loop F. Assessing myocardial perfusion with Alunex during coronary artery bypass surgery: technical considerations and safety of aortic root injections. *J Cardiothorac Vasc Anesth* 1996;10:713–718.
44. US Department of Health and Human Services, Public Health Service, Food and Drug Administration, Office of Device Evaluation, Center for Devices and Radiologic Health. Radiological devices panel meeting, February 24, 1997. Available at: <http://www.fda.gov/ohrms/dockets/ac/97/transcript/3262t1.pdf>. Accessed June 7, 2013.
45. Center for Devices and Radiologic Health. Approval package for: application number 21-064. Available at: http://www.accessdata.fda.gov/drugsatfda_docs/nda/2001/21-064_Definity_pharmr_P1.pdf. Accessed June 7, 2013.
46. Lindner JR, Song J, Jayaweera AR, Sklenar J, Kaul S. Microvascular rheology of Definity microbubbles after intra-arterial and intravenous administration. *J Am Soc Echocardiogr* 2002;15:396–403.
47. Boolani H, Main ML. Update on contrast echocardiography: safety and utility. *Curr Cardiovasc Imaging Rep* 2012;5:410–419.
48. Kusnetzky LL, Khalid A, Khumri TM, Moe TG, Jones PG, Main ML. Acute mortality in hospitalized patients undergoing echocardiography with and without an ultrasound contrast agent: results in 18,671 consecutive studies. *J Am Coll Cardiol* 2008;51:1704–1706.
49. Main ML, Ryan AC, Davis TE, Albano MP, Kusnetzky LL, Hibberd M. Acute mortality in hospitalized patients undergoing echocardiography with and without an ultrasound contrast agent (multicenter registry results in 4,300,966 consecutive patients). *Am J Cardiol* 2008;102:1742–1746.
50. Herzog CA. Incidence of adverse events associated with use of perflutren contrast agents for echocardiography. *JAMA* 2008;299:2023–2025.
51. Wei K, Mulvagh SL, Carson L, Davidoff R, Gabriel R, Grimm RA, Wilson S, Fane L, Herzog CA, Zoghbi WA, Taylor R, Farrar M, Chaudry FA, Porter TR, Irani W, Lang RM. The safety of Definity and Optison for ultrasound image enhancement: a retrospective analysis of 78,383 administered contrast doses. *J Am Soc Echocardiogr* 2008;21:1202–1206.
52. Dolan MS, Gala SS, Dodla S, Abdelmoneim SS, Xie F, Cloutier D, Bierig M, Mulvagh SL, Porter TR, Labovitz AJ. Safety and efficacy of commercially available ultrasound contrast agents for rest and stress echocardiography: a multicenter experience. *J Am Coll Cardiol* 2009;53:32–38.
53. Gabriel RS, Smyth YM, Menon V, Klein AL, Grimm RA, Thomas JD, Sabik EM. Safety of ultrasound contrast agents in stress echocardiography. *Am J Cardiol* 2008;102:1269–1272.
54. Shaikh K, Chang SM, Peterson L, Rosendahl-Garcia K, Quinones MA, Nagueh SF, Kurrelmeyer K. Safety of contrast administration for endocardial enhancement during stress echocardiography compared with noncontrast stress. *Am J Cardiol* 2008;102:1444–1450.
55. Abdelmoneim SS, Bernier M, Scott CG, Dhoble A, Ness SA, Hagen ME, Moir S, McCully RB, Pellikka PA, Mulvagh SL. Safety of contrast agent use during stress echocardiography: a 4-year experience from a single-center cohort study of 26,774 patients. *JACC Cardiovasc Imaging* 2009;2:1048–1056.
56. Abdelmoneim SS, Bernier M, Scott CG, Dhoble A, Ness SA, Hagen ME, Moir S, McCully RB, Pellikka PA, Mulvagh SL. Safety of contrast agent use during stress echocardiography in patients with elevated right ventricular systolic pressure: a cohort study. *Circ Cardiovasc Imaging* 2010;3:240–248.
57. Exuzides A, Main ML, Colby C, Grayburn PA, Feinstein SB, Goldman JH. A retrospective comparison of mortality in critically ill hospitalized patients undergoing echocardiography with and without an ultrasound contrast agent. *JACC Cardiovasc Imaging* 2010;3:578–585.
58. Wei K, Main ML, Lang RM, Klein A, Angeli S, Panetta C, Mikati I, Lee LV, Bernstein JA, Ahmad M. The effect of Definity on systemic and pulmonary hemodynamics in patients. *J Am Soc Echocardiogr* 2012;25:584–588.
59. Weiss RJ, Ahmad M, Villanueva F, Schmitz S, Bhat G, Hibberd MG, Main ML. CaRES (Contrast Echocardiography Registry for Safety Surveillance): a prospective multicenter study to evaluate the safety of the ultrasound contrast agent Definity in clinical practice. *J Am Soc Echocardiogr* 2012;25:790–795.