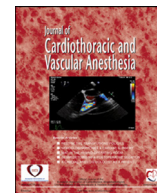


Contents lists available at [ScienceDirect](#)

Journal of Cardiothoracic and Vascular Anesthesia

journal homepage: [www.jcvaonline.com](http://www.jcvaonline.com)

## Editorial

## Ultrasound-Enhancing Agent Safety: Understanding the New Food and Drug Administration Warning on Polyethylene Glycol

IN APRIL 2021, the Food and Drug Administration (FDA) issued an alert stating ultrasound-enhancing agents (UEA) should not be administered to patients with known hypersensitivity reactions to polyethylene glycol (PEG). In response, several societies, including the International Contrast Ultrasound Society and the American Society of Echocardiography, have issued and published statements providing education and guidance on this topic.<sup>1</sup>

Contrast echocardiography uses UEA, which contain acoustically active microbubbles that rely upon stable cavitation after exposure to ultrasound to produce opacification after intravenous injection.<sup>2</sup> The use of contrast echocardiography has increased over the past decades, as its safety and diagnostic benefit have become clear.<sup>3</sup> Agitated saline, the original UEA, uses relatively unstable air microbubbles that are readily absorbable to aid in visualization of intracardiac or intrapulmonary shunts.<sup>4</sup> Current UEA contain shells composed of either a lipid monolayer or albumin that encapsulate a core containing inert high-molecular-weight gas.<sup>5</sup> The lipid monolayer that forms the shell of the acoustically active microbubbles present in UEA provides intravenous stability and persistence during circulation. The lipid monolayer may contain various types of lipids, including di-acyl lipids and lipids with a PEG group, which aid in the production of the lipid-coated microbubbles and minimize the interaction between the microbubble shell and blood.

Commercially available UEA include Optison (GE Healthcare), Definity/Lumify (Lantheus), Sonovue/Lumason (Bracco), and Sonazoid (GE Healthcare), with the latter three employing a lipid monolayer as the shell. Sonazoid by GE Healthcare currently is not approved for use within the United States. Clinical indications for contrast echocardiography include identification and assessment of intracardiac masses, qualitative and/or quantitative assessment of either the left or right ventricle, myocardial perfusion imaging, and delineation of shunting.<sup>5</sup> Newer applications include providing imaging assistance as a part of a structural heart disease program within the catheterization laboratory and targeted delivery of

therapeutic intervention.<sup>6,7</sup> Contrast echocardiography can salvage the diagnostic quality of suboptimal noncontrast echocardiograms and has shown particular utility in the care of critically ill populations as a safe alternative imaging technique performed at the bedside in patients who are coronavirus 2019-positive or are on extracorporeal membrane oxygenation.<sup>8-10</sup> Furthermore, UEA are safe to use in patients with renal function impairment; while other imaging modalities, such as contrast-enhanced computer tomography and magnetic resonance imaging, rely upon potentially nephrotoxic contrast agents.<sup>11</sup>

Though relatively safe, there are examples of cardiopulmonary events and severe immunologic responses after UEA injection. The FDA went so far as to issue a black box warning for UEA beginning in 2007. In the intervening years, the language of the black box warning has softened as the safety of UEA use in contrast echocardiography has emerged more clearly and several ultrasound societies have lobbied the FDA to remove the warning altogether.<sup>12</sup> The recently released FDA *MedWatch* alert, which forms the basis of the new ASE expert consensus statement, identified 11 cases of presumed type-I immediate hypersensitivity reactions (HSR) to UEA in patients with known PEG hypersensitivity during decades of pharmacosurveillance.<sup>1</sup> Type-I HSR are mediated through mast cell activation and degranulation, and subsequent stimulation of a complex, multiorgan inflammatory cascade. Due to its use as an excipient in thousands of medical products and household items, as well as an active medication in many bowel preparations, patient exposure to PEG-containing products is nearly ubiquitous. In the absence of confirmatory detection of anti-PEG Immunoglobulin E (IgE), the true incidence of IgE-mediated type-I HSR to PEG is unknown and the prevalence of PEG hypersensitivity in the general population is underestimated. Case reports of confirmed IgE-mediated PEG hypersensitivity implicate a wide variety of medications and range of systemic reactions including urticaria, wheezing, dyspnea, angioedema, hypotension, and syncope.<sup>13,14</sup> There is only a single case report of enzyme-linked immunosorbent

assay (ELISA)-confirmed IgE-mediated HSR to PEGylated liposomal perflutren, resulting in dyspnea, urticaria, hypotension, and need for intensive care unit admission.<sup>15</sup>

Distinquished from IgE-mediated type-I HSR, mast cell activation and degranulation can occur as a result of complement activation-related pseudoallergy (CARPA). This mechanism of severe allergic reaction has been linked to modern pharmacologic agents, using nanoparticulate vehicle technologies such as radiocontrast media, PEGylated liposomal drugs such as UEA, and possibly lipid nanoparticle-based mRNA vaccine against severe acute respiratory syndrome coronavirus 2 (SARS-CoV-2).<sup>3,16,17</sup> Based on similarities in clinical symptoms between liposomal doxorubicin in the late 1990s and liposomal complement activation in animals and human studies, Szebeni, in 2001, described CARPA as an independent category of “receptor-mediated” mast cell activation.<sup>18</sup> Symptoms of CARPA are similar to those of classic allergies and IgE-mediated type-I reaction, with the most notable difference from IgE-mediated reaction being lack of presensitization requirement, ability for spontaneous resolution of symptoms over time, and absent-to-mild reactions with repeated exposure. The incidence of CARPA after the administration of UEA remains speculative, as clinical differentiation of underlying pathologic mechanism is difficult, but severe allergic and anaphylactoid reactions with UEA have been described around 0.01% and 0.004%, respectively, with a majority being attributed to CARPA.<sup>19,20</sup> Treatment of CARPA remains similar to that of allergic or anaphylactic reactions with epinephrine, steroids, antihistamines and supportive measures, whereas avoidance of large boluses or rapid injections are thought to mitigate the incidence.<sup>3</sup>

In spite of the possibility of IgE-mediated type-I HSR or CARPA, lipid-based UEA have an excellent safety profile, with an estimated incidence of serious reactions occurring in approximately one per 10,000 doses.<sup>19</sup> The MedWatch alert recommended that patients with known hypersensitivity to PEG should not be given lipid-based UEA; however, this does not change the practical utilization of UEA for several reasons. First, many patients are unaware of their allergy to PEG. Allergies attributable to PEG may be difficult to diagnose due to the presence of PEG in many commonly used compounds (eg, mRNA vaccines, cosmetics, laxatives). Second, although PEG allergies may be underreported, the frequency of severe reactions to UEA still is estimated to be very low based on surveillance data. Third, the imaging team responsible for UEA administration already should be trained in cardiopulmonary resuscitation and, thus, be able to intervene if a severe allergic response occurs. Although the new recommendation from the ASE highlights the importance of screening patients for PEG allergy before administration of lipid-based UEA, it likely will not change clinical practice significantly and serves as an important reminder for echocardiography teams to be able to diagnose and treat allergic reactions.

All three of the FDA-approved intravenous UEA available in the United States are injectable suspensions of gas-containing microspheres that opacify intracardiac structures to improve endocardial border delineation.<sup>3</sup> Of these, Definity

and Lumason are both suspensions of lipid microspheres containing perflutren and sulfur hexafluoride, respectively. They both should be avoided in patients with known or suspected hypersensitivity to the lipid microspheres or its components, which include PEG.<sup>1</sup> By contrast, Optison is a suspension of human serum albumin microspheres containing perflutren and does not contain PEG.<sup>21</sup> Optison should be avoided in patients with known or suspected hypersensitivity to perflutren, blood, blood products, or albumin. Transesophageal or epicardial echocardiography may be employed to address particular clinical concerns and may alleviate the need for UEA when used. In addition, if intravenous administration of UEA is contraindicated and there is sufficient clinical need, cardiac MRI with or without gadolinium contrast can be considered, as well as contrast-enhanced CT.<sup>22</sup>

In summary, the use of UEA in contrast echocardiography has significant diagnostic utility, a broad clinical application, and a robust safety profile. There are reports of IgE-mediated type-I HSR and CARPA reactions to the PEG components of the lipid shell of UEA. Optison uses albumin rather than a PEG-containing lipid shell to encapsulate its inert high-molecular-weight gas and is a viable alternative in patients allergic to PEG. Administration of PEG-containing UEA in patients with known hypersensitivity is contraindicated. However, many patients may be unaware of their allergy status to PEG given its ubiquitous presence in many products. As such, teams administering UEA should be trained to identify and manage potential immunologic reactions in patients undergoing contrast echocardiography. When PEG-containing UEA are contraindicated, consider using Optison or alternative imaging modalities, such as cardiac MRI or contrast-enhanced computed tomography.

### Conflict of Interest

None.

Tiffany M. Williams, MD, PhD  
Reed Harvey, MD  
Wolf B. Kratzert, MD, PhD  
Matthew A. Fischer, MD  
Jacques Neelankavil, MD

*Department of Anesthesiology and Perioperative Medicine, David Geffen School of Medicine, University of California, Los Angeles, Los Angeles, CA*

### References

- 1 Lindner JR, Belcik T, Main ML, et al. Expert consensus statement from the American Society of Echocardiography on hypersensitivity reactions to ultrasound enhancing agents in patients with allergy to polyethylene glycol. *J Am Soc Echocardiogr* 2021;34:707–8.
- 2 Weiss RJ, Ahmad M, Villanueva F, et al. CaRES (Contrast Echocardiography Registry for Safety Surveillance): A prospective multicenter study to evaluate the safety of the ultrasound contrast agent Definity in clinical practice. *J Am Soc Echocardiogr* 2012;25:790–5.
- 3 Muskula PR, Main ML. Safety with echocardiographic contrast agents. *Circ Cardiovasc Imaging* 2017;10:e005459.

- 4 Gramiak R, Shah PM, Kramer DH. Ultrasound cardiography: Contrast studies in anatomy and function. *Radiology* 1969;92:939–48.
- 5 Porter TR, Mulvagh SL, Abdelmoneim SS, et al. Clinical applications of ultrasonic enhancing agents in echocardiography: 2018 American Society of Echocardiography guidelines update. *J Am Soc Echocardiogr* 2018;31:241–74.
- 6 la Canna G, Scarfò I, Arendar I, et al. Targeting alcohol septal ablation in patients with obstructive hypertrophic cardiomyopathy candidates for surgical myectomy: Added value of three-dimensional intracoronary myocardial contrast echocardiography. *J Clin Med* 2021;10:2166.
- 7 Ebel H, Goetze S, Weida A, et al. Impact of ultrasound contrast agent during transoesophageal echocardiography on the sizing of the left atrial appendage. *Open Heart* 2021;8:e001403.
- 8 Hazem L, Stephen S, Andrew S. Contrast-enhanced echocardiography application in patients supported by extra corporeal membrane oxygenation (ECMO): A narrative review [e-pub ahead of print]. *J Cardiothorac Vasc Anesth*. doi: 10.1053/j.jvca.2021.04.031. Accessed 2021.
- 9 Main ML, Fu JW, Gundrum J, et al. Impact of contrast echocardiography on outcomes in critically ill patients. *Am J Cardiol* 2021;150:117–22.
- 10 Argulian E, Sud K, Bohra C, et al. *J Am Soc Echocardiogr* 2020;33:1054–5.
- 11 Girometti R, Stocca T, Serena E, et al. Impact of contrast-enhanced ultrasound in patients with renal function impairment. *World J Radiol* 2017;9:10–6.
- 12 Patil HR, Main ML. Revisiting the safety profile of echocardiography contrast agents. *American College of Cardiology Expert Analysis* 2016.
- 13 Cox F, Khalib K, Conlon N. PEG that reaction: A case series of allergy to polyethylene glycol. *J Clin Pharmacol* 2021;61:832–5.
- 14 Stone CA, Liu Y, Relling M v, et al. Immediate hypersensitivity to polyethylene glycols and polysorbates: More common than we have recognized. *J Allergy Clin Immunol Pract* 2019;7:1533–40.
- 15 Krantz MS, Liu Y, Phillips EJ, et al. Anaphylaxis to PEGylated liposomal echocardiogram contrast in a patient with IgE-mediated macrogol allergy. *J Allergy Clin Immunol Pract* 2020;8:1416-9.e3.
- 16 Moghimi SM. A two-stage poly(ethylenimine)-mediated cytotoxicity: implications for gene transfer/therapy. *Mol Ther* 2005;11:990–5.
- 17 Szebeni J. Complement activation-related pseudoallergy: A stress reaction in blood triggered by nanomedicines and biologicals. *Mol Ther* 2014;61:163–73.
- 18 Szebeni J. The Interaction of Liposomes with the Complement System. *Critical Reviews in Therapeutic Drug Carrier Systems* 1999;1.
- 19 Wei K, Mulvagh SL, Carson L, et al. The safety of Definity and Optison for ultrasound image enhancement: A retrospective analysis of 78,383 administered contrast doses. *J Am Soc Echocardiogr* 2008;21:1202–6.
- 20 Khawaja OA, Shaikh KA, MH Al-Mallah. Meta-analysis of adverse cardiovascular events associated with echocardiographic contrast agents. *Am J Cardiol* 2010;106:742–7.
- 21 Fix SM, Nyankima AG, McSweeney MD, et al. Accelerated clearance of ultrasound contrast agents containing polyethylene glycol is associated with the generation of anti-polyethylene glycol antibodies. *Ultrasound Med Biol* 2018;44:1266–80.
- 22 Ammar M, Mahmoudi S, Chikh MA, et al. Endocardial border detection in cardiac magnetic resonance images using level set method. *J Digit Imaging* 2012;25:294–306.